

## PHOTO QUIZ

## A troubled heart

J.A Janson<sup>1,2</sup>, D. Valstar<sup>1</sup>, G.J. de Grooth<sup>2</sup>, D.J. van Westerloo<sup>1</sup>

<sup>1</sup>Department of Intensive Care Medicine, Leiden University Medical Center, Leiden, the Netherlands

<sup>2</sup>Department of Cardiology, Leiden University Medical Center, Leiden, the Netherlands

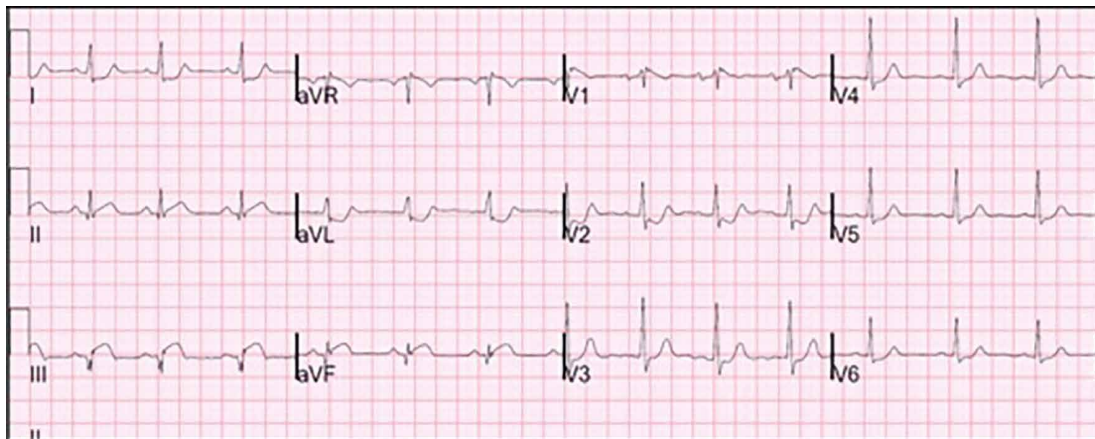
### Correspondence

D. van Westerloo - djvanwesterloo@lumc.nl

An 81-year-old male patient presented to our emergency department after referral from an outside hospital. His previous medical history was relevant for chronic renal insufficiency, pulmonary embolism and hypertension. The patient had been complaining of intermittent chest pain during the day which became persistent in the last two hours before presentation. The chest pain was somewhat atypical since it was present on both sides of the chest. Additionally, he complained of progressive

dyspnoea on exertion in the last couple of weeks. At presentation his heart rate was 100 beats/min and blood pressure was 95/60 mmHg. Laboratory results showed an elevated troponin level of 4287 ng/l and was otherwise unremarkable. Electrocardiogram (ECG) at presentation is shown below (*figure 1*).

*What is your diagnosis based on this ECG?*



**Figure 1.** ECG at presentation

### Answer

You will find the answer on page 173 of this issue.