

CASE REPORT

The clinical pentad of thrombotic thrombocytopenic purpura

K van Hee, FN Polderman

Department of Intensive Care, Jeroen Bosch ziekenhuis, 's Hertogenbosch, The Netherlands

Abstract - Thrombotic thrombocytopenic purpura (TTP) is a rare condition with variable clinical symptoms. The diagnosis of TTP should be considered in patients with unexplained neurological symptoms or acute renal insufficiency in combination with thrombocytopenia and anaemia. Its pathophysiology is based on autoantibodies which inhibit the cleaving of Von Willebrand Factor. This leads to thrombocytopenia and micro-angiopathic haemolytic anaemia. Without treatment TTP has a high mortality. The first line of treatment is plasma exchange, often combined with corticosteroids. If the patient is unresponsive to this then further treatment options are rituximab, other immune suppressants and as a last resort splenectomy can be considered. This report presents a patient with all the clinical characteristics of TTP, which is rarely seen these days.

Keywords - Thrombotic thrombocytopenic purpura, TTP-HUS, rituximab, plasma exchange

Introduction

Even in the ICU department, the rare diagnosis of thrombotic thrombocytopenic purpura (TTP) should be considered, because of its variable clinical presentation and the need for immediate treatment. The main clinical features are often neurological impairment and/or acute renal insufficiency. Diagnosis and treatment should be based on micro-angiopathic anaemia and thrombocytopenia. Other diagnoses to be considered are disseminated intravascular coagulation, drug toxicity, autoimmune haemolysis, malignant hypertension. There are no clear data on the incidence of TTP in the ICU department. Here we present a case with all the classical clinical symptoms of the disease.

Case report

A 31-year old male with no prior medical history presented to the Emergency Department (ED) of our hospital with disorientation, lethargy and jaundice which he had had for several hours. During the previous five days he had had flu-like symptoms with fever, loose stools, nausea and vomiting. The patient's general practitioner had diagnosed a urinary tract infection for which he had prescribed doxycycline and co-trimoxazole several days before presentation. At the ED the patient was confused and very agitated. His blood pressure was 95/65 mmHg, heart rate 112 beats/minute and temperature 37 degrees Celsius (later at the ICU 39.1 degrees Celsius). Physical examination showed no abnormalities except for jaundice. Because of the patient's extreme agitation and decreased consciousness, he was sedated and intubated. Laboratory results showed a Coombs-negative haemolytic anaemia (with fragmentocytes), leucocytosis, thrombocytopenia, and decreased renal function (*table 1*). At the

ED the diagnosis of TTP was considered and plasmafiltration (PF) was started (60ml/kg/day) together with prednisolon (1.5 mg/kg/day) as soon as the patient was admitted to the ICU. PF was started instead of plasma exchange (PE), since in our hospital it is easier to initiate PF because the equipment is available. The next day ADAMTS-13 activity was 3% (range 30%-200%) and ADAMTS-13 antibodies were detected, supporting the diagnosis. ADAMTS-13 is a metalloproteinase which is responsible for cleaving Von Willebrand Factor and therefore plays a role in platelet aggregation, which will be explained in more detail in the paragraph on pathophysiology. During the first four days the patient's platelet count increased and LDH decreased (*Figure 1*). However, on day five, his platelet count decreased, LDH increased, and neurological symptoms persisted (extreme agitation when sedatives were reduced). Therapy was switched to PE on day six, since this is the first line of treatment according to the Dutch guidelines for TTP treatment (Dutch Society of Haematology [1]). Because there was still no neurological improvement and ADAMTS-13 activity was 0% (antibodies still positive) rituximab (375mg/m² weekly) was added on day nine. The next day the patient's neurological symptoms improved and he could be

Table 1. Laboratory results on admission

Hb	2,7	mmol/L	Ureum	17,1	mmol/L
Leucocytes	19	10 ⁹ /L	Creatinin	182	µmol/L
Thrombocytes	12	10 ⁹ /L	Na	136	mmol/L
Reticulocytes	184	10 ⁹ /L	K	4,2	mmol/L
Haptoglobin	<0,08	G/L	Bilirubin	63	µmol/L
APTT	24	Sec	LD	2638	U/L
PT	17	Sec	CRP	20	mg/L
Fibrinogen	4,3	G/L	Procalcitonin	0,27	Ng/ml
Fragmentocytes	100	/1000 ery	Direct Coombs	neg.	(-)

Correspondence

FN Polderman

Email: f.polderman@jzbz.nl

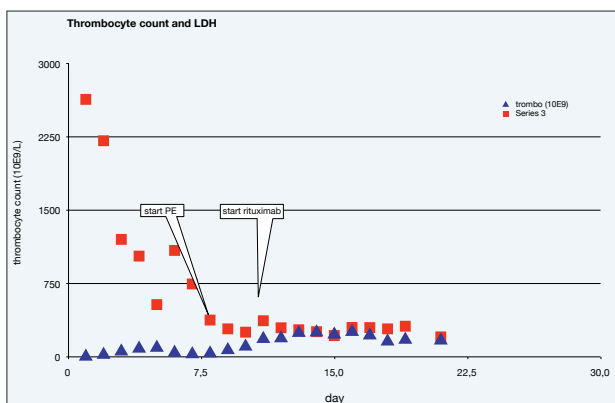
extubated. On day fourteen the patient was discharged from the ICU to the clinical department, where he received PE four more times, on days 16, 19, 21 and 23 respectively. The patient showed full clinical recovery and normalisation of platelet count. On day 21, the ADAMTS-13 activity was 51% and ADAMTS-13 antibodies were negative. After 27 days the patient was discharged from hospital.

Thrombotic thrombocytopenic purpura

Background

Thrombotic thrombocytopenic purpura (TTP) is a life-threatening disorder characterized by thrombocytopenia and microangiopathic anaemia. It is also called the Moschcowitz syndrome, after the doctor who first described the disease in 1925 [2]. It is a rare disease with an annual incidence of approximately 45/1,000,000 person/years and a male:female ratio of 1:2 [3]. The disease manifests itself predominantly in patients between 20 and 40 years of age [1]. TTP is often mentioned together with the Hemolytic Uremic Syndrome (HUS) or referred to as TTP-HUS, as the presenting features are essentially the same. These comprise of a characteristic set of clinical features and laboratory findings; micro-angiopathic haemolytic anaemia, thrombocytopenia, acute renal insufficiency, neurological abnormalities and fever. When neurological features are dominant and acute renal failure is minimal or even absent, some consider these clinical features to represent "classical TTP". The name HUS is used when renal failure is dominant (as is often the case in children following a bout of diarrhoea caused by *E. Coli* O157:H17) [2]. There are, however, many patients with both neurological abnormalities and renal failure, for which the term TTP-HUS is used. Whether the name TTP or HUS is used, the pathophysiologic changes are the same, as indeed is the initial treatment.

Figure 1. Thrombocyte count and LDH



Course in time of thrombocyte count and LDH after admission in hospital. Points marked where PE and rituximab treatment were started. Before start of PE treatment consisted of PF.

Pathophysiology

In adults approximately one third of TTP cases are idiopathic. The rest is considered to have been triggered by a clinical situation, such as pregnancy, drug ingestion, infection, autoimmune disorders or after haemopoietic stem cell transplantation [4]. The pathogenesis, at least in a significant number of cases, is related to the formation of autoantibodies against ADAMTS-13 (A Disintegrin-like And Metalloproteinase with Thrombospondin type 1 motifs 13), which cleaves Von Willebrand Factor (VWF). VWF is a multimeric glycoprotein present in the blood plasma, produced by endothelial cells. One of its main functions is the adhesion of platelets to wound sites. When VWF is not cleaved by ADAMTS-13, ultra large VWF-multimers remain in circulation. This leads to intravascular platelet aggregation, resulting in thrombosis in the microvasculature, which characterizes TTP [5, 6] (Figure 2). It has been suggested, however, that ADAMTS-13 deficiency alone is not enough to cause TTP. In the literature a two hit model has been proposed in which another trigger (e.g. infection or pregnancy) activates microvascular endothelial cells and causes secretion of VWF- multimers and P-selectin expression leading to the formation of thrombi [6]. There are also mutations in the ADAMTS-13 gene leading to congenital deficiency (Upshaw-Shulman syndrome), however, this is rare [5,7].

Diagnosis

Diagnosis and treatment should be based on micro-angiopathic haemolytic anaemia and thrombocytopenia, without an alternative cause such as disseminated intravascular coagulation, drug toxicity, autoimmune haemolysis, malignant hypertension or haematopoietic stem cell transplantation. The other clinical features, neurological symptoms, renal involvement and fever are considered to be relative late events and should be avoided if possible by early start of treatment. Diagnosis and treatment should thus be based on haemolytic anaemia, thrombocytopenia, increased LDH, negative Coombs-test, and the presence of fragmentocytes.

ADAMTS-13 testing is not considered useful in diagnosing TTP, since the fraction of severe deficiency (activity < 5%) varied from 33% to 100% in several studies among patients with idiopathic TTP [5,8]. Furthermore, patients with secondary TTP hardly ever have ADAMTS-13 deficiency. And last but not least, most laboratories cannot perform ADAMTS-13 assays rapidly. The usefulness of ADAMTS-13 and ADAMTS-13 antibody testing during treatment remains unclear [5]. It can be used however to monitor a patient after remission in order to estimate the risk of relapse [1].

Treatment

Treatment with plasma exchange results in an overall survival of 80%. At present this is considered first line treatment. Its mode of action is twofold: it removes ADAMTS-13 autoantibodies and VWF-multimers from the circulation of the patient and supplies the patient with ADAMTS-13 via the plasma of a healthy donor. The separation of the above-mentioned components from the

blood plasma is based on gravity by means of centrifugation of the plasma. Analysis of several reports has shown, however, that approximately 40% of patients diagnosed with TTP do not show ADAMTS-13 deficiency. Treatment with plasma exchange in these cases was also effective [4]. Therefore, PE exchange is considered effective for all cases of TTP as first line therapy. An alternative therapy to PE is plasma filtration (PF). In a few hospitals it is easier to initiate PF because the equipment is already available in the hospital. With PF the blood plasma is led through a large pore filter (usually 0,2-0,6 micron), through which both the ADAMTS-13 antibodies and the Von Willebrand Factor multimers are filtered out of the plasma. There have been a few studies done with plasma filtration, which do not indicate this therapy to be inferior [9-11]. However, it is not considered as standard therapy in the treatment of TTP. More data should be collected to prove its effectiveness [11]. The addition of corticosteroids has shown to be useful and is often prescribed together with PE [2,7]. It is assumed that corticosteroids suppress the autoantibodies against ADAMTS-13. The response to PE is monitored by the platelet count. Usually the platelet count increases after the second or third episode of PE. Neurological improvement may be the first sign of response. LDH levels decrease after the start of treatment but a return to normal is less predictable [7]. The literature shows that 10-20% of cases do not respond to PE [8]. Furthermore, the relapse risk in ADAMTS-13 deficiency is estimated at 41% at 7.5 years; the highest risk is during the first year after recovery [3,7]. Relapses rarely occur in patients without ADAMTS-13 deficiency.

When PE is regarded ineffective i.e. no increase of platelets, recurrent thrombocytopenia or clinical deterioration, the first choice for second line of therapy is the addition of immunosuppressants such as cyclosporine, vincristine or

rituximab. Currently rituximab is mostly used as first choice [1,7]. Rituximab is a chimeric monoclonal antibody directed against the CD-20 antigen, which is present on B-cell lymphocytes. Its mode of action is antibody dependent cellular cytotoxicity, direct antibody dependent apoptosis and complement dependent cytotoxicity. In cases of TTP, this results in elimination of ADAMTS-13 antibody producing B-cells [12]. There are also reports, however, in which rituximab was effective in cases of TTP without anti-ADAMTS-13 antibodies [12]. In these cases its mode of action remains unclear. Rituximab appears to be effective as treatment of refractory or relapsing TTP, with complete clinical and laboratory response in approximately 95% of patients. Also an increase in ADAMTS-13 and disappearance of anti-ADAMTS-13 antibodies has been seen [5]. It should be noted that the above mentioned studies consisted of small series and case-reports. The use of rituximab is not without risk, because it is known to have significant side effects like angio oedema after infusion, high risk of infection and bone marrow depression [13].

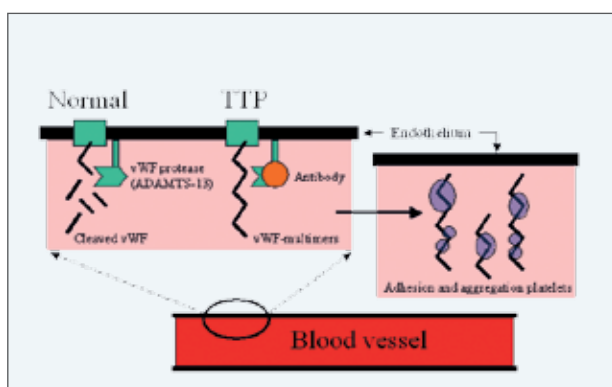
A third option therapy for TTP is splenectomy. This used to be first line therapy before the effectiveness of PE was discovered. It has been suggested that the effect of splenectomy is based on elimination of an important source of B-lymphocytes producing inhibitory ADAMTS-13 autoantibodies [14]. In the literature there is much controversy on whether splenectomy should be considered, with concerns regarding its efficacy and safety. Currently it is indicated as a last resort therapy in refractory or frequently relapsing TTP [2,1,14,15].

Discussion

This case demonstrates a patient with the clinical pentad of symptoms for TTP on presentation at the ED. The first treatment started was Plasma Filtration (PF) instead of PE, since this was logistically more practical. PF can be performed using a machine for haemodialysis (present at our hospital) and for PE a separate machine should be transported from another hospital. However, when the platelet count decreased again after five days of PF, treatment was switched to PE. When no clinical improvement on switching to PE and continuing absence of ADAMTS-13 was observed after nine days, the patient was considered to be non-responsive. Therefore, rituximab was added to the therapy, according to the Dutch TTP guidelines [1]. After rituximab was started, the patient clinically improved within a day and platelet count increased steadily. Whether this effect can be subscribed to rituximab is debatable.

The diagnose of TTP, should, also in the ICU department, be considered in all patients with unexplained neurological symptoms or acute renal insufficiency combined with haemolytic anaemia and thrombocytopenia, since it is a disease with high mortality if left untreated. Immediate treatment with PE is indicated.

Figure II. Pathophysiology thrombotic thrombocytopenic purpura (TTP)



Left (normal situation): after the release from the endothelium of the Von Willebrand Factor (vWF) multimer it is cleaved by vWF-protease
Right (in TTP): vWF-protease is not capable to cleave the vWF multimer because of the presence of an antibody. Platelets easily adhere and aggregate to the multimer resulting in thrombosis in the microvasculature

References

1. TTP-richtlijn 2009, <http://www.hematologienederland.nl/book/export/html/345>
2. Lammler B, Kremer Hovinga JA, Alberio L. Thrombotic thrombocytopenic purpura. *J Thromb Haemost* 2005;3:1663-75
3. Peyvandif F, Palla R, Lotta LA. Pathogenesis and treatment of acquired idiopathic thrombotic thrombocytopenic purpura. *Haematologica* 2010;95: 1444-7
4. Elliot MA, Heit JA, Pruthi RK, Gastineau DA, Winters JL, Hook CC. Rituximab for refractory and or relapsing thrombotic thrombocytopenic purpura related to immune-mediated severe ADAMTS13 deficiency: a report of four cases and a systematic review of the literature. *Eur J Haematol* 2009;83:365-72
5. Sadler JE. Von Willebrand factor, ADAMTS13, and thrombotic thrombocytopenic purpura. *Blood* 2008;112:11-8
6. Galbusera M, Noris M, Remuzzi G. Inherited thrombotic thrombocytopenic purpura. *Haematologica* 2009;94:166-70
7. George JN. How I treat patients with thrombotic thrombocytopenic purpura. *Blood* 2010;116:4060-9
8. Vesely SK, George JN, Lammler B, et al. ADAMTS13 activity in thrombotic thrombocytopenic purpura-hemolytic uremic syndrome: a relation to presenting features and clinical outcomes in a prospective cohort of 142 patients. *Blood* 2003;101:60-80
9. Bruni R, Giannini G, Lercari G, et al. Cascade filtration for TTP : an effective alternative to plasma exchange with cryodepleted plasma. *Transfus Sci* 1999;21:193-9
10. Valbonesi M., Giannini G. Nine years of cascade filtration for thrombotic thrombocytopenic purpura. *Ther Apher Dial* 2004;8:87-92
11. Wollersheim JAHG, Novotny VMJ, Fijnheer R. Verwijdering van 'ultra large' von Willebrand factor door plasmaferese met filtratie-en centrifugatietechniek bij patiënten met trombotische thrombocytopenische purpura. *Tijdschr bloedtransfusie*. 2009;2:93-9
12. Caramazza D, Quintini G, Abbene I, et al. Relapsing or refractory idiopathic thrombotic thrombocytopenic purpura-hemolytic uremic syndrome: the role of rituximab. *Transfusion*. 2010;50:2753-60
13. Farmacotherapeutisch kompas, <http://www.fk.cvz.nl>
14. Hovinga JA, Studt JD, Biassiuti FD, et al. Splenectomy in relapsing and plasma-refractory acquired thrombotic thrombocytopenic purpura. *Haematologica*. 2004;89:320-4
15. Dubois L, Gray DK. Splenectomy: Does it still play a role in the management of thrombotic thrombocytopenic purpura? *Can J Surg* 2010;53:349-55